




The View Ahead

The Publication for Progressive Dental Professionals by Ahead Diagnostics

Winter 2004

Trivia



According to law in Providence, RI it is illegal to sell toothbrushes on Sunday. However, the sale of toothpaste and mouthwash is legal seven days a week.

Utilization of Volumetric (3D) Imaging for Evaluation of the Maxillary Incisive Canal



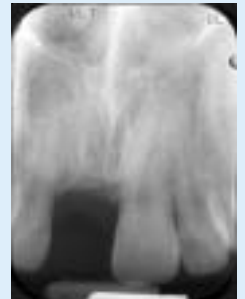by Joan Pluchinsky, CRT

The general opinion about the size of incisive canals is that they are approximately 2 to 3 mm in diameter and vary little from one person to another. It has been thought that the size was stable by age 15–18 when other growth is complete. However, with the advance of 3-dimensional imaging technology, it is clear that the canal's size may vary dramatically between individuals. This information could be of great importance to any dentist who is considering placement of implants in the area of #8-9.

We have noted the maxillary incisive canal to be as large as 5 to 8 mm, especially in people younger than 25 years of age. No apparent abnormalities were present with these individuals so it may be normal growth pattern.

The following images illustrate how traditional 2-dimensional radiography failed to indicate the presence of a large canal.

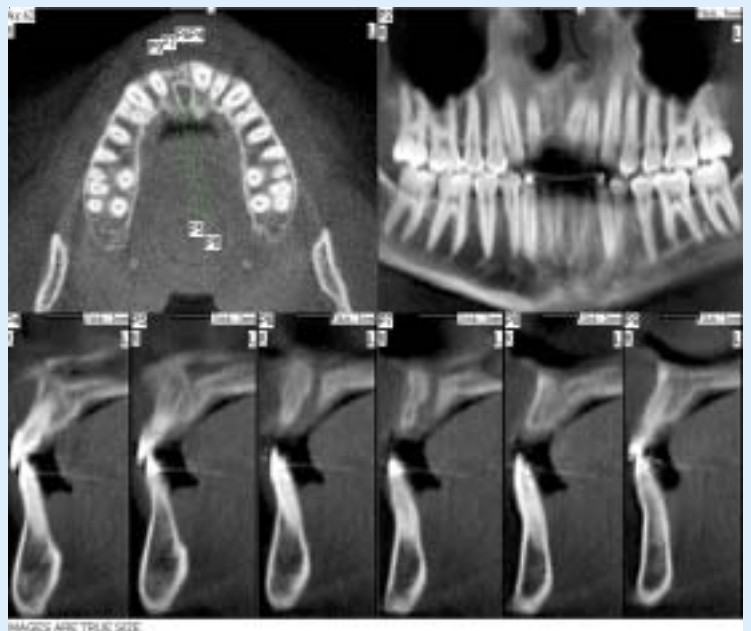
Case study: 22 year old male with traumatic loss of tooth #8 several years earlier. The patient was ready to proceed with a permanent implant-based restoration. This periapical radiograph was taken by the periodontist prior to referral for advanced imaging. Although the width appears sufficient for implant placement in this area, concern about the depth of the ridge and the history of trauma to the area prompted the referral to Ahead Diagnostics.



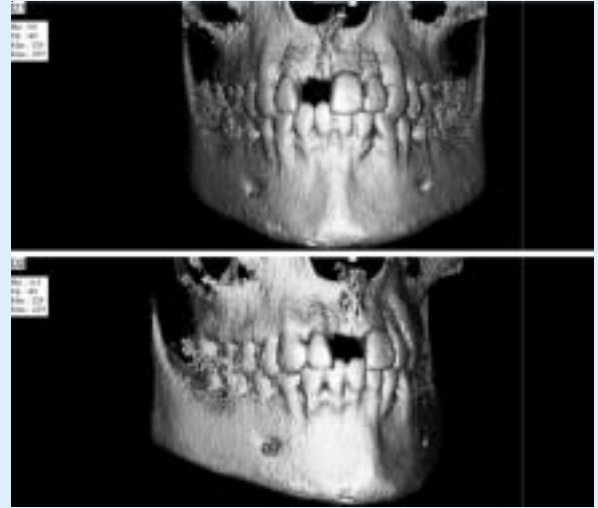
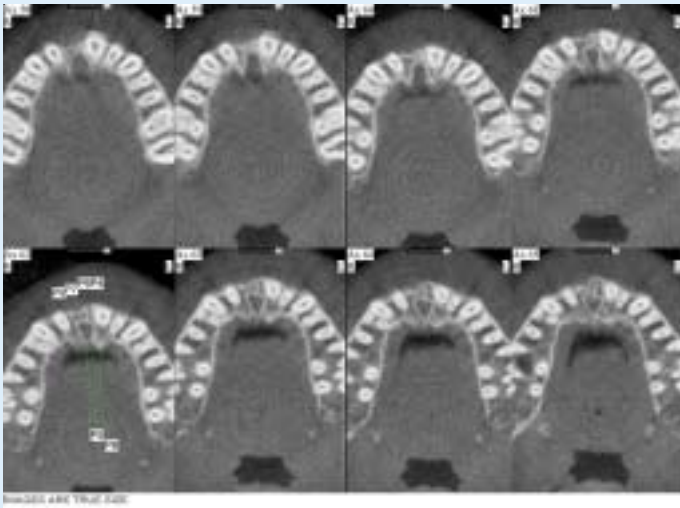
The patient was imaged at Ahead Diagnostics with the NewTom 9000. The NewTom 9000 is the first and still the only volumetric imaging device developed specifically for dentistry. It features a cone-beam radiation path providing a series of 360 images pulsed in a single, complete rotation. Reconstruction of the data is performed subsequent to the patient's dismissal utilizing accompanying software, and the data can be viewed in multiple perspectives including axial, transaxial, panoramic, and others.

The axial view, upper left, indicates the position of the cross-sectional images. These 2 mm thick cross-sectional images were cut at precise, 2 mm intervals through the maxilla in the area of interest. This results consecutive data with no loss of information.

Note the centimeter ruler embedded in every image. The canal can be seen on 3 cross-sectional images. The size is 5 mm x 6 mm. Detection of this anatomic structure was vital to a good surgical result.



IMAGES ARE TRUE SIZE



One millimeter axial cuts stepped through the patient's anatomy from inferior to superior illustrate the size of the maxillary incisive canal, and the encroachment on the planned area of restoration.

These 3-dimensional views offer a spatial perspective not available with traditional imaging. This image can be rotated to be viewed from any angle, including a lingual perspective.

Volumetric (3-dimensional) imaging eclipses the shortcomings associated with traditional imaging. Although the periapical radiograph is the gold standard for caries detection in dentistry, relying solely on the periapical radiograph in this case would have been misleading. Advanced imaging can assist the dentist placing implants in radiographic visualization of important anatomic structures. It allows the dentist to solve the unknowns prior to formulating a treatment plan. The practitioner is able to communicate with the patients fully the risks and benefits associated with the plan of care, and the patients will have a better understanding of the expected outcome of the treatment.

About the author: Joan Pluchinsky is a dental radiologic technologist with over 25 years experience in conventional and advanced imaging at the University of Texas Dental School at San Antonio. She is currently employed at Ahead Diagnostics in Austin, Texas.

What a referring dentist has to say about Ahead Diagnostics:

"Ahead Diagnostics provides a service that has greatly impacted my practice. The digital imaging has facilitated diagnosis and treatment planning of more difficult implant cases. This has translated into reduced time, stress, and the ability to provide a greater range of services for our patients."

Thanks!

Robert Ramirez, DDS
Periodontist
Austin, TX



Ahead Diagnostics, Ltd.
Explore True Dimensions
7800 N. Mopac, Suite 115
Austin, TX 78759
512-795-9950 / fax 512-795-9951
www.aheaddiagnostics.com

In addition to the volumetric scanner, we also offer digital diagnostic photography, and intraoral, panoramic, and cephalometric imaging and tracing.

Have a diagnostic problem? Let us help you visualize and explore the area of concern. Diagnostic interpretation and report by an Oral and Maxillofacial Radiologist is available for any image.